

Paediatric Cardiology

Paediatric Electrocardiography Guideline

Staff relevant to:	Medical & Nursing staff working within EMCHC & PICU & Paediatrics
Written by:	Dr Suhair Shebani Guideline Lead
Reviewed by:	Suhair Shebani
Approval date:	May 2023
Revision Date	May 2026
Version:	3
Trust Ref:	C168/2016

Contents

1. Introduction and who this guideline applies to.....	1
2.1 Patient Approach.....	2
2.2 Chest Electrode Positions.....	2
2.3 Chest Positions for Patients with Dextrocardia.....	3
3. Paediatric Electrocardiography (ECG), Background information;.....	3
The Standard ECG.....	3
Deflections and Intervals.....	4
Order of ECG interpretation.....	5
I. Rate and Rhythm.....	5
II. A-V Conduction.....	5
III. Atrial depolarization.....	5
IV. Ventricular depolarization.....	6
Table 3.1: Normal voltages in mV in precordial leads:.....	6
Calculation of QRS.....	7
V. Ventricular Repolarization.....	7
VI. Ventricular hypertrophy.....	8

1. Introduction and who this guideline applies to

This guideline should be used when performing electrocardiography on patients under the age of 16.

2. Guideline standards and procedures

2.1 Patient Approach

- ❖ Note the patient's name, consultant, date of birth and hospital unit number before commencing the test. Check with the parents/guardians/patient whether they are correct. Using the correct information available, input information into ECG machine along with the date and if they are an inpatient or an outpatient.
- ❖ Explain the ECG procedure to the parents/guardians ('a record of the heart beat which is painless'), and where possible, explain the ECG to the child in simple terms (depending on the age of the child).
- ❖ Make sure the patient is as comfortable as possible. For children under the age of 4/5 years depending on how 'wiggly' they are, flat is a desirable position, but obviously if the child is too wiggly or uncooperative, sitting the child on mum/dads knee is acceptable.
- ❖ Where appropriate, chat to the child and use distraction toys to keep the child interested and relaxed and hopefully as still as possible.
- ❖ Attach the electrodes to the limb and chest positions as follows:

Arm electrodes should be placed on the upper or lower arms, and SHOULD NOT be applied to the shoulders or clavicles. For total accuracy, arm electrodes should be attached to the wrists and leg electrodes to the ankles. However, this may not be possible if the child is wiggly and/or unco-operative in which case upper and lower limbs are satisfactory.

- ❖ Application of electrodes – no skin preparation is usually required for paediatric patients. However, the contact of electrodes may be reduced on newborn babies in which case very gentle wiping of the electrode area with a Mediswab for example, may help the contact. In babies/small children, the standard self-adhesive electrodes may be too large in which case use paediatric electrodes.

2.2 Chest Electrode Positions

V1 (red electrode) to be placed in V4R position V2

(yellow electrode) to be placed in V1 position V3

(green electrode) to be placed in V2 position. No

standard V3 to be taken

V4, V5 and V6 as normal

- ❖ Once electrodes are in place, attach the ECG leads and ensure the cable is in a secure position.
- ❖ When ready to record the ECG, if possible encourage the child to keep still whilst recording. If your patient is too wiggly, use distraction techniques with toys to keep the child occupied while recording.

- ❖ A standard 12 lead ECG is recorded with a lead II rhythm strip. For children with supraventricular tachycardia or atrial fibrillation/flutter, then a V1 rhythm strip is recorded.
- ❖ Once complete remove electrodes and check that the recording is labelled correctly. Ensure ECG is shown to medical staff.

2.3 Chest Positions for Patients with Dextrocardia

- ❖ Follow the ECG protocol as usual recording with normal chest positions.
LIMB LEADS REMAIN THE SAME.
- ❖ Then repeat the ECG using the following positions on the right side of the chest.

V1R- fourth intercostal rib space to the left sternal edge

V2R – fourth intercostal rib space to the right sternal edge

V3R – (over age of 16 years) midway between V2R and V4R

V4R – fifth intercostal space on the midclavicular line

V5R – at the same level as V4R on the anterior axillary line.

V6R – at the same level as V4R and V5R in the mid-axillary line.

3. Paediatric Electrocardiography (ECG), Background information;

Indications: assessment of every cardiac patient and in paediatric practice on suspicion of a structural cardiac, rhythm problem

The Standard ECG

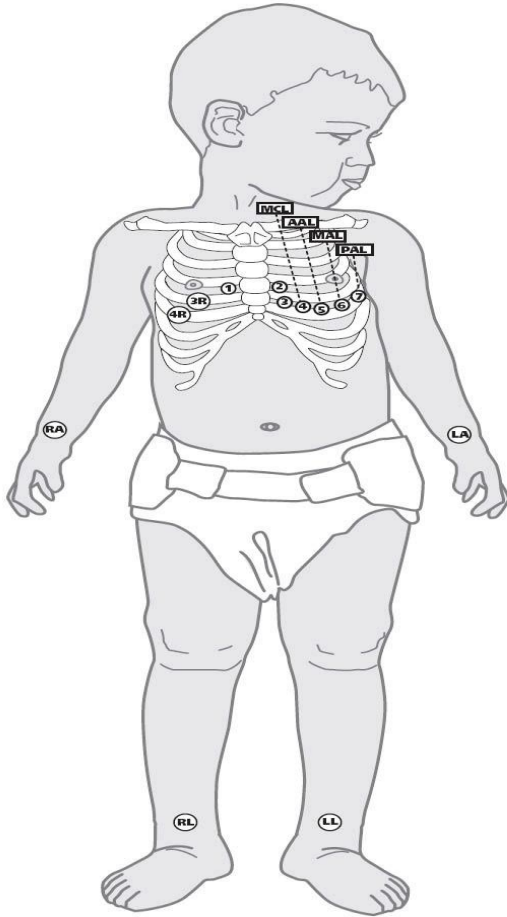
Electrode positions See figure 1

- Standard (I,II,III) and unipolar leads (aVR, aVF, aVL) same as adults
- Precordial leads V1-V6, with V4R up to 12 years
- In dextrocardia V6R to V1
- A rhythm strip with 3 leads or lead II if assessing rhythm disturbances
- If leads are very abnormal consider lead mal-placement

Recording

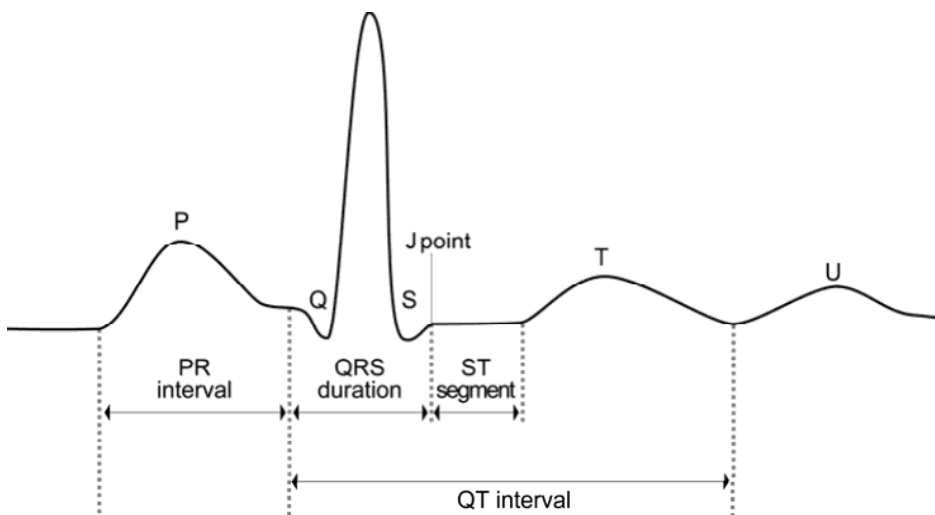
- Speed 25mm /sec (1small square = 0.04sec)
- At full standardisation amplitude of 10mm= 1mV
- Recording at 50mm/sec helps in interval measurement

figure 1:



© University Hospitals of Leicester NHS Trust

Deflections and Intervals: figure 2:



Order of ECG interpretation

- I. Rate and rhythm
- II. AV-conduction
- III. Atrial de/repolarization
- IV. Ventricular depolarization
- V. Ventricular repolarization
- VI. Hypertrophy, enlargement

Make sure the ECG corresponds to the patient in question with date on and patient DOB.

I. Rate and Rhythm

Heart Rate:

- Influenced by body temp, autonomic nervous system, activity, age.
- $HR = 300 / \text{No of large squares each } 0.2 \text{ sec}$
- or $1500 / \text{No of small squares each } 0.04 \text{ sec}$
- Normal age variations
- Premature and LBW: 77-211 bpm
 - 3-33% of neonates have APCs or VPCs
 - FT neonate: min 55-75 to 220 bpm
 - Older children min 44-68, max 132-196, 15-40% APCs, VPCs 3% non-sustained VT
 - Fit adolescents especially athletes 31-55 bpm
 - Sinus pauses <3sec, 1st degree and 2nd degree type 1 heart block can be a normal variation.

Rhythm:

- Regular, irregular, or regular with intermittent predictable irregularity
- Relationship of P waves to the QRS complexes
- Sinus P wave = atrial depolarisation from top to bottom and from right to left
→ □ +ve in I, II, aVF, -ve in aVR
- Reversal of P wave vector = situs inversus.

II. A-V Conduction

- 1st degree Heart Block = prolonged PR interval
- 2nd degree Heart Block
 - Type 1
 - Type 2
- 3rd degree Heart Block = CHB

No conduction from A to V = no relation between P and QRS complexes

III. Atrial depolarization

The P wave:

- Initial RA, terminal LA components
- Duration: infancy: 0.04-0.07 s, adolescence: 0.06-0.1 s
- Tallest in leads II, V4R, V1 upper limit 2.5 mm
- Abnormal pattern: anomalous pacemaker

Atrial hypertrophy:

- RAH: spiked P-wave > 2.5 mm in II, V4R, V1.
 - severe PS, PA, TA, PHT

- LAH : notched P-wave or large –ve component in V4R, V1
 - MV disease, LVOTO, 1ry LV cardiomyopathy

IV. Ventricular depolarization

The QRS complex:

Duration: 0-8y <80 msec = 2 small squares
>8 y < 90 msec

Duration prolonged

- Rt or Lt BBB
- Ventricular pre-excitation
- Ventricular pace-maker
- Ventricular hypertrophy
- Intraventricular conduction delay: CMP, ARVD
- Q wave
- R and S

Ventricular depolarisation: variation of R/S voltages with age

Table 3.1: Normal voltages in mV in precordial leads:

	V _{4R}	V ₁		V ₃	V ₄	
	R	R	S	R	R	S
Birth	8 (4-12)	12 (5-20)	10 (0-20)	9 (2-20)	5 (1-13)	6 (0-15)
6 months	5 (2-7)	11 (3-17)	10 (1-25)	20 (10-28)	14 (5-25)	3 (0-10)
1 year	4 (0-7)	9 (2-16)	10 (1-12)	20 (5-30)	14 (5-25)	3 (0-7)
10 years	2.5 (0-6)	5 (1-12)	10 (1-25)	20 (5-40)	16 (5-30)	2 (0-5)

Q wave = depolarization of IVS from L to R

- Leads: II, III, aVF, V5, V6
- Measures 2-3 mm >4 mm is abnormal, duration <40 msec
- Prominent Q waves in LVH, BVH
- Q in other leads is rare; seen in HOCM, ALCAPA, CCTGA
- In CCTGA Q is seen in V4R, V1 and absent from V5,V6

R and S: size is determined by ventricular wall thickness, it varies with age

QRS axis = Direction of maximal electrical force during depolarization

Method 1: using leads I,II

- Plot R-S
- Drop perpendiculars from those axes
- Line from origin through intersection is the electrical axis

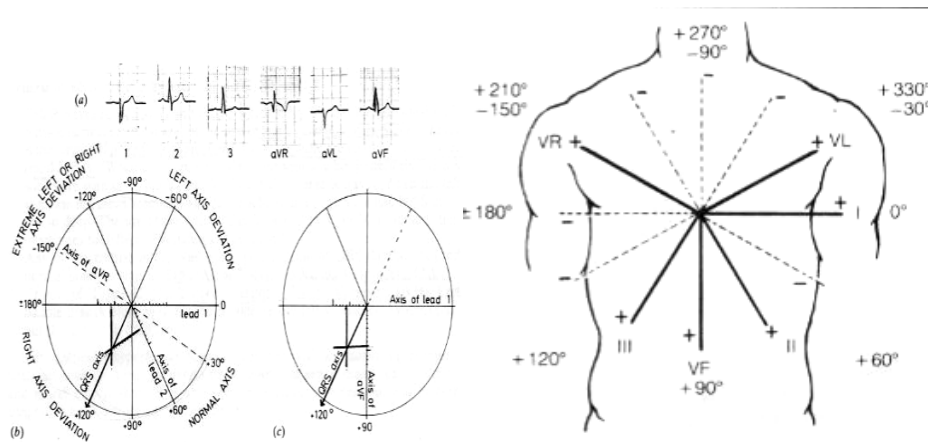
Method 2: using leads I, aVF

- Result of R-S in aVF should be X 1.3

Method 3:

- Choose any limb lead with R=S
- Electrical axis will be at right angles to the axis of that lead

Calculation of QRS



V. Ventricular Repolarization

- ST-T- wave abnormalities:
 - ST segment elevation > 0.1 mV, depression < -0.05 mV
 - Affected by Electrolyte disturbance, myocarditis, pericarditis, MI, drugs
- QT interval: from start of QRS to end of T-wave
 - HR and age dependent
 - $QTc = QT \text{ measured} / \sqrt{RRt}$ of previous RR interval in lead II (Bazett's formula) 0-6mo < 0.490 sec, $> 6mo < 0.425$ sec
 - $\uparrow QT$: Familial: Romano Ward, Jervell & Lange Neilsen syndromes and electrolytes, drugs, metabolic causes.

➤ T wave

- Should measure $\frac{1}{4}$ - $\frac{1}{3}$ of R-wave
- Upright in V4R, V1 +/- V2, V3 then inverted after 3rd day of life
- Remains inverted in Rt chest leads as we approach adolescence it becomes upright in V2, V3 (5-15y)
- Normally inverted in aVR, +/- aVF, III
- T wave is always inverted in V1 unless there is a pathology
- Inverted T in other leads: ventricular hypertrophy, myocardial disease, pericarditis and severe hypothyroidism

➤ U wave

VI. Ventricular hypertrophy

Criteria for LVH:

1. Mild LVH: Sum of S in V1 + R in V5 or V6 > 30mm under 1 yr or > 40 mm > 1 yr
2. Moderate LVH (1) + prolonged QRS or flat T-wave in V5, V6
3. Severe LVH (1) + (2) plus T-wave inversion in V5, V6 Examples:
Aortic valve disease,
Moderate size VSD,
Large PDA,
MR,
Systemic hypertension,
Congestive and obstructive Cardiomyopathy

Criteria for RVH:

1. Mild RVH: RAD, R above normal limits in V4R, V1 R>S in V1 after age of 12 months
S in V6 > normal of age: 15mm in 1st week, 10 mm 1-24 wk, 7 mm 6-12 months, 5 mm >1yr
2. Moderate RVH: (1) + prolonged QRS and upright T wave in V4R, V1 after 3 days of age
3. Severe RVH: tall R waves in V4R, V1 QRS>90 msec and deep T-wave inversion in V4R, V1
Examples: PS, PHT, Fallot
D/D
RBBB, WPW

Biventricular hypertrophy:

1. Tall R and deep S in V3, V4 (R+S > 50 mm at any age)
2. LVH + wide or bifid R in V4R, V1 > 8 mm
3. RVH + T wave Inversion V5-6 (T upright in V1-2) or q wave ≥ 3 mm in V5-6
4. Criteria of RVH, LVH

Example: 3 year old with large VSD and dynamic pulmonary hypertension
R+S in V4 =70mV

Specific Electrocardiographic Diagnosis:

- \uparrow P-R interval: Ebstein's AVSD
- CHB: Congenital, CCTGA, post op for AVSD, TOF
- RBBB: ASD, Ebsteins post ventriculotomy: VSD, TOF
- LAD: 0 to -90 in pink baby: AVSD, in blue baby: TA. -90 to -180: CAVSD and DORV
- RAH with absence of RV dominance in a cyanosed baby = Hypoplastic RV QRS axis
0 to +90: PA, intact septum
0 to -90 TA
- Cyanosed baby with PHT but no RVH: HLHS
- Deep Q consider HOCM or ALCAPA
- Presence of q in V1, V4R and absence in V5, 6 = CCTGA
- Deep T wave inversion in V5-6 with no murmur: Cardiomyopathy or EFE

3. Education and Training

None

4. Monitoring Compliance

None identified at present

5. Supporting References

None

6. Key Words

Electrocardiography, ECG, Electrodes, PR Interval, QRS complex

The Trust recognises the diversity of the local community it serves. Our aim therefore is to provide a safe environment free from discrimination and treat all individuals fairly with dignity and appropriately according to their needs.

As part of its development, this policy and its impact on equality have been reviewed and no detriment was identified.

CONTACT AND REVIEW DETAILS	
Guideline Lead (Name and Title) Suhair Shebani – Paediatric cardiologist Claire Sansome – CCS04 Deborah Ip - Senior Chief Cardiac Physiologist Carla Blunt - Chief Cardiac Physiologist	Executive Lead: Chief Nurse
REVIEW RECORD	
Description Of Changes (If Any) No changes	